

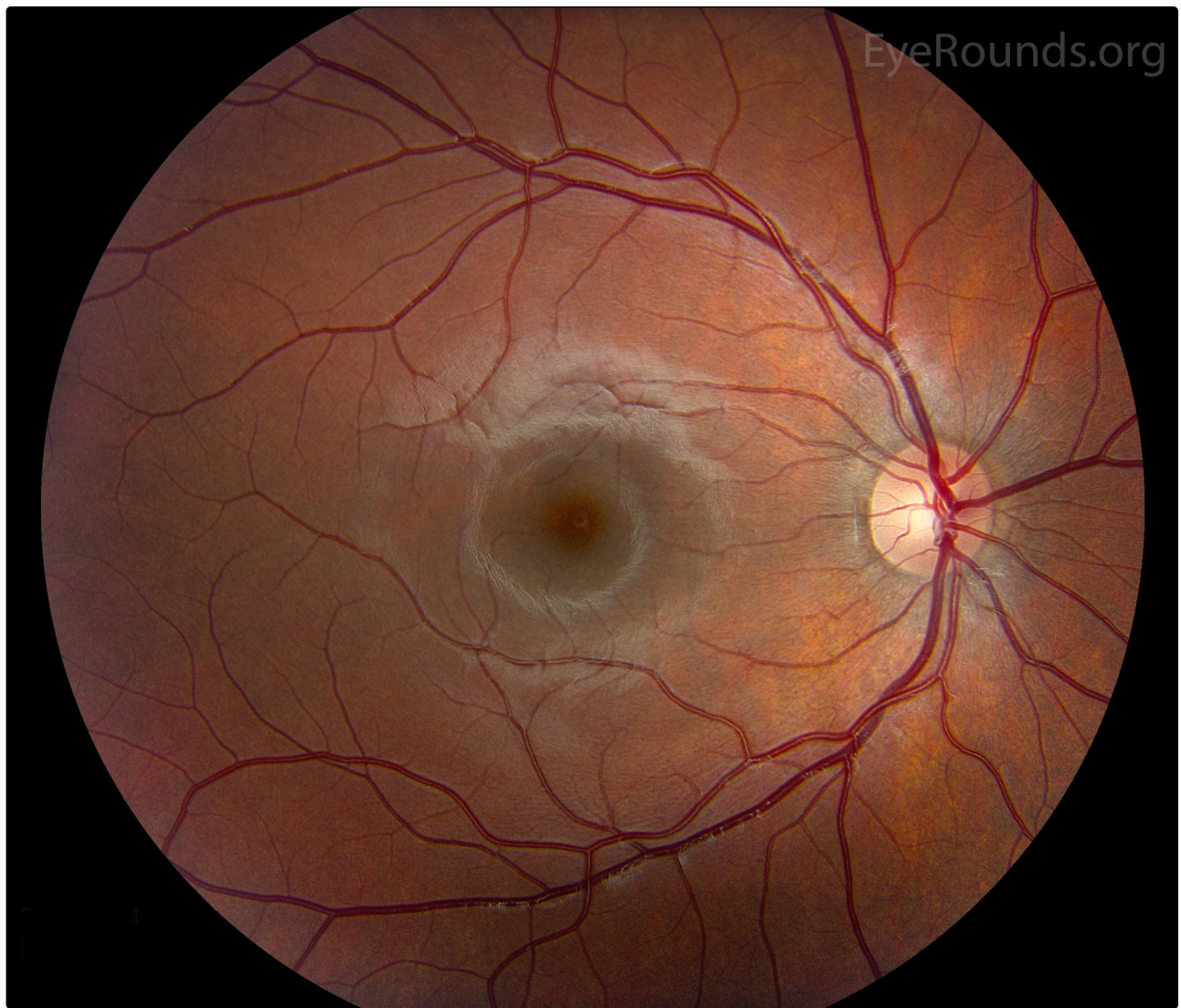
Normal fundus - child

Category(ies): Pediatrics, Retina

Contributor: [Jesse Vislisel, MD](#)

Photographer: Cindy Montague, CRA

This is the appearance of a normal fundus in a 10-year-old child. Notice the prominent sheen of the robust retinal nerve fiber layer, a normal finding in children. This is especially visible around the fovea and vasculature in this photograph.



Normal Child Fundus

[Enlarge](#)

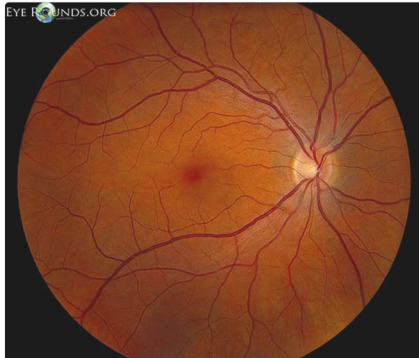[Download](#)



Ophthalmic Atlas Images by EyeRounds.org, The University of Iowa are licensed under a Creative Commons Attribution-NonCommercial-NoDerivs 3.0 Unported License.



Related Articles



[Related Atlas Entry: Normal Fundus \(Adult\)](#)

Address

University of Iowa
Roy J. and Lucille A. Carver College
of Medicine
Department of Ophthalmology and
Visual Sciences
200 Hawkins Drive
Iowa City, IA 52242

[Support Us](#)

Legal

Copyright © 2019 The University of
Iowa. All Rights Reserved
[Report an issue with this page](#)
[Web Privacy Policy](#) |
[Nondiscrimination Statement](#)

Related Links

[Cataract Surgery for Greenhorns](#)
[EyeTransillumination](#)
[Gonioscopy.org](#)
[Iowa Glaucoma Curriculum](#)
[Iowa Wet Lab](#)
[Patient Information](#)
[Stone Rounds](#)
[The Best Hits Bookshelf](#)

EyeRounds Social Media

Follow



Receive notification of new cases,
[sign up here](#)
[Contact Us](#)
[Submit a Suggestion](#)